



Original Research Article

External Dacryocystorhinostomy with Silicone stent in Anatomical and Functional primary acquired nasolacrimal duct obstruction

Vasu Narasimha Naik^{1,*}, Kumar V²

¹Dept. of Ophthalmology, District Health and Family Welfare Office, Chamarajanagara, Karnataka, India

²Malleswaram Eye clinic, Malleshwaram, Bangalore, Karnataka, India



ARTICLE INFO

Article history:

Received 07-05-2020

Accepted 03-06-2020

Available online 30-06-2020

Keywords:

Complications

EXDCR

PANDO

Silicone tube.

ABSTRACT

Purpose: To compare the benefits and complications of External dacryocysto rhinostomy (EXDCR) with Silicone tube (ST) intubation in anatomical primary acquired naso lacrimal duct obstruction (APANDO) and functional primary acquired naso lacrimal duct obstruction (FPANDO) patients.

Materials and Methods: Patients with epiphora/discharge/mucocele are grouped into group A (APANDO) and group B (FPANDO) based on diagnostic probe test, positive syringing and Fluorescein Dye Disappearance (FDD) test. Both group underwent EXDCR with ST intubation. Patients were evaluated for subjective and objective resolution of epiphora/discharge/mucocele, complications and subjective satisfaction at the end of 6 months.

Result: There were 23 patients each in group A and group B and no difference in demographic and laterality of eye involvement. Epiphora was common presentation in FPANDO (91%) and discharge in APANDO (57%). ($P=0.01$). The success rate is 78.3% (18/23) in group A and 86.9% (20/23) in group B and the difference is not significant ($P=0.69$). Tube related complications are high in group B 82.6% ($P=0.01$) and inflammation related complications in group A 61.2% ($P=0.49$). In group A 82.6% (19/23) and group B 73.9% (17/23) were satisfied with the procedure ($P=0.72$). Tube related complication and additional financial burden are the main factors for dissatisfaction in group B ($P=0.72$)

Conclusion: Use of silicone tube does not alter the success rate of EXDCR in APANDO and FPANDO. Preoperative counseling and eye health educations are very important before doing such procedure on rural population.

© 2020 Published by Innovative Publication. This is an open access article under the CC BY-NC license (<https://creativecommons.org/licenses/by-nc/4.0/>)

1. Introduction

Epiphora is the commonest presenting symptom in Primary acquired naso lacrimal duct obstruction (PANDO). Both anatomical and functional blocks are attributed for epiphora. Most commonly accepted explanation for anatomical PANDO (APANDO) is downward and upward inflammation of the lacrimal duct leading to fibrosis of the duct wall. Altered lacrimal pump action, reduced capillary function of the lacrimal puncta and canaliculi are the reason for functional PANDO (FPANDO).^{1,2}

The gold standard treatment for PANDO is External dacryocystorhinostomy (EXDCR) with success rate of 59%

- 99%.³⁻⁶ Explained causes for the failure of EXDCR are both anatomical and functional. Anatomical causes are canalicular narrowing, acute angulation of canaliculi at sac junction, fibrotic closure of the common canalicular opening, granulation tissue in the osteal opening, abnormal position of the anastomosis, fibrosis and cicatrization of anastomosis, intranasal synechia and non detectable causes.^{2,5,7-10} Functionally altered lacrimal pump system in the form of functional loss of sac vacuum portion of lacrimal tear pump, reduced canalicular pump action, sac reduced venturi effect at the nasal opening due to reduced rhinostomy movement.^{2,7}

Many modifications have been attempted to improve the success rate of EXDCR. Altering the size and the number

* Corresponding author.

E-mail address: gunjanna@gmail.com (V. N. Naik).

of the lacrimal sac and mucosal flaps.^{8,11} Intra operative use of Mansoura T tube,¹² Silicone tube intubation,^{3,4,13} Intra operative TMA (Triamcinolone) injection^{10,14} and intra operative use of MMC (Mitomycin C)⁹ with variable success rate.

Silicone stent has been widely used in all types of nasolacrimal duct surgery since the period it introduced by Gibbs.¹⁵ Attributed mechanism of actions of silicone tube are both anatomical and functional. Anatomically being inherent material reduces granulation tissue formation, Prevents common canalicular obstruction, mechanically increases the diameter of lumen of the punctum- canaliculi and straighten various bends in canaliculi.^{2,3,6,16,17} Functionally increases the lacrimal fluid flow along the surface of the stent, facilitates the capillary flow of puncta and canaliculi, by improving the good oppose of upper and lower puncta enhance the lacrimal pump action and increase lacrimal flow during closure phase of blinking.^{13,16,17}

On review of literature some studies have drawn our attention. A retrospective study by Neena et al.⁷ 46 cases had functional PANDO following EXDCR and they were intubated with silicone tube and reported 63% success rate with no tube related complications. Two separate prospective studies from Elmonem et al.¹² and Kim et al.¹³ all their patients had anatomically patent but functionally failed EXDCR and all had resolution of the epiphora following silicone tube intubation with very low tube related complication (<10%). Other prospective study by Nuhoglu et al.⁵ their group had non complicated cases of both anatomical and functional type of PANDO. In non complicated cases 96% cases had resolution following stent intubation and 29% cases developed many tube related complications. Another study by Saiju et al.⁴ 100 cases had anatomical PANDO among them 44 cases underwent EXDCR with tube intubation. In 90% of the cases epiphora resolved without any tube related complications. This diversity of observation on silicone tube related complications made us to do a comparative prospective study on efficacy and complications of primary EXDCR with silicone tube intubation in anatomical and functional PANDO.

2. Materials and Methods

This is a prospective, comparative and interventional study done in District referral hospital. This study was conducted from September 2017 to December 2019. The study adhered to declaration of Helsinki 1975, study was approved from review and ethical committee of the hospital. All patients were informed about the merits and demerits of the procedure. Written consent was taken from patients. All enrolled patients' demography, detailed history, comprehensive preoperative eye examination and slit lamp examination for lid abnormalities, punctal position and punctal abnormalities are done.

Tests for lacrimal duct patency are regurgitation test, diagnostic probing test, syringing and Fluorescein dye disappearance (FDD) test. Schirmert test I and Tear breakup time (BUT) for tear function. Based on these test patients are grouped into Anatomical PANDO group A and functional PANDO group B. Exclusion criteria are acquired secondary NLD block, punctual stenosis, entropion, ectropion, lagophthalmos, trichiasis and blepharitis. Previous dacryocystorhinostomy (DCR) of any type, dry eye, corneal surface disorder and age group below 18 years of age.

All patients had their blood pressure, random blood sugar, BT, CT and ENT consultation to rule out any nasal pathology. Those patients who were on oral blood thinning or/and anticoagulants were asked to stop them 1 week before the surgery.

All patients were operated by single surgeon. Surgical steps of EXDCR are as described by Dupuy - Dutemps and Bourget modified with only single anterior flap of lacrimal sac and nasal mucosa.^{8,11} Under sterile surgical area 2:1 mixture of 2% lidocaine and 0.5% bupivacaine injected around medial canthal area. Nasal pack with 1.25cm size ribbon gauze soaked in 30 ml 4% xylocaine with 2 ampules of inj adrenaline 1:10000 and left till the time of silicone tube stenting. A 10 – 12 mm curved incision taken 8-10 mm from the medial canthus all along anterior lacrimal crest starting from middle point of the medial palpebral ligament. Layer by layer skin, subcutaneous tissue, orbicularis oculi were separated to expose the medial end medial palpebral ligament. Palpebral ligament disinserted. Lamina papyracea was gently perforated with bone periosteum elevator. Around 10 -15 mm diameter size osteotomy done with serial sized bone rounge. With Bowmans probe 00 medial wall of lacrimal sac tented and a single large anterior flap was made. Same size anterior flap made in nasal mucosa. A bicanalicular Silicone tube (Aurolac - Aurolab - Madurai - India) intubated trough upper and lower puncta, retrieved through common canaliculi, osteotomy and into nasal cavity. Two ends of the tube were tied in so that there is no snaring effect on punctae, unnessasry looping into medial fornix or hanging out of the nostril. Both the flap were trimmed as per the requirement and joined together. Palpebral ligament refixed, orbicularis muscle and skin were sutured layer by layer. For all suturing 6 0 vicryl was used. Fresh nasal pack put and pad bandage applied. Postoperatively oral Diclofenac + paracetamol, Cefixime 200 mg BID for 5 days given. Topically steroid - antibiotic drops five times daily, antibiotic ointment application twice daily for the sutured wound for 6 weeks. Follow up done on 1 day, 1 week, 4 week and monthly for 6 months. Nasal pack was removed on first post operative day, skin sutures on 10th day and silicone tube between 16 – 24 weeks post operatively. During each visit patients were evaluated for subjective and objective resolution of symptoms. Subjectively, patients

free from epiphora or/and discharge. Objectively anatomical success by patency on syringing and functional by positive FDD test. Success was considered with both subjective and objective resolution at the end of 6 months. Patient opinion on financial burden and subjective satisfaction of the procedure also recorded. The results are analyzed by NCSS 2020 Statistical Software (2020). NCSS, LLC. Kaysville, Utah, USA and The results are presented with group mean compared with two tailed Fishers exact test and statically significance by P value.

3. Results

There were 46 eyes from 46 patients. The mean age of the patient is 48.3 (19 -78) yrs. Female: Male ratio is 1.9:1. Right eye was involved in 58.7 % (27/46) and 41.3 % (19/46) in Left eye. The Mean duration of symptom is 9.4 (4-16) months. Common Presenting symptom was epiphora in 74% (34/46) cases, discharge 15% (7/46) cases and mucocele 11% (5/46) in cases. Success rate of 89.1% (41/46) at the end of 6 months. Major complications observed during the follow up are tube extrusion (silicone road extrusion or tube looping from stent road) in 10.9%(5/46) cases, granuloma around the tube 6.5% (3/46) cases, punctual slit 2.1% (1/46) and tube loss 4.3% (2/46). Cumulative minor complications (cornela erosion, conjunctival erosion, cosmetic blemish, discomfort and FB sensation) are seen in 37% (17/46) cases and these complications resolved following proper remedial procedures.(Table 2) Regarding patients satisfaction about the procedure and financial burden 21.7% (10/46) responded negatively. Their reasons were additional cast for the tube and tube related complications.

On comparison of two groups there is no major difference in mean age, in gender, laterality of eye involvement and duration of symptoms between two group. Epiphora was the commonest presentation in B group 91.3%(21/23) patients compare to 47.8% (11/23) in group A and discharge /mucocele was more common presentation in group A 43.5% (10/23) compare to group B 8.7%(2/23) ($P=0.01$).(Table 1)

Success rate at the end of the 6 months was 78.3% (18/23 cases) in group A and 86.9% (20 /23 cases) in group B and the difference is small ($P= 0.69$). Among the 21.6%(5/23) cases of failed procedure in group A, 8.7% (2/23) cases had granuloma around the tube at 3 months follow up, 4.3% (1/23) case had tube loss at 1 month follow up, 4.3%(1/23) case had subjective epiphora at 2 month follow up and 4.3% (1/23) case after the tube removal on 5 months follow up. Three cases underwent restenting and 2 cases with granuloma received injection of 0.5 ml of Triamcinolone 40mg/ml and epiphora resolved. These 5 cases are excluded from success group.

In group B 13% (3/23) cases had failure of the procedure. One elderly female patient who noticed the loop of the

stent in the medial canthal area on 3rd week post op period. Thinking that some worm and pulled out easily and reported with stent in hand and epiphora. This patient was restented and the stent was fixed to the nasal cartilage. Second patient had recurred epiphora after removal of the stent on 2nd month follow up. This patient was restented and relieved of symptoms. The third patient had ephipora on 4th month follow up, on examination there was thick granuloma occluding the anastomosis area. Through the nasal route 0.5ml of Triamcinolone 40mg/ml was injected into granuloma and epiphora relieved. These 3 cases are excluded from success group.

Cumulative stent related complication like looping of the stent (silicone road extrusion) (Figure 1), cosmetic blemish, punctual slitting, canalicular snaring, corneal erosion, conjunctival erosion, discomfort and FB sensation were less in group A 21.7% (5/23) patients compare to group B 82.6 %(19/23) patients and the difference is significant ($P= 0.001$). Among 4 cases of stent looping in group B patients, 1 case had looping on 6th post operative day, 2 cases after 2 months of post operative period. The 4th case middle aged male patient had small loop of tube and was playing with his grand child and the child has pulled the loop at 1 month follow up. In all these cases tube was repositioned and fixed to nasal cartilage with 6 0 prolene till the period for removal. In group A one patient had looping of stent on 3rd week post operative period. He was cleaning the medial canthus with bud and accidentally pulled the stent it was fixed to nasal cartilage.

Inflammation related complications like difficulty in removing the stent, granuloma around the anastomosis area and adhesion in the nasal cavity was more in Group A patients 30.4% (7/23) compare to group B patients 17.4% (4/23) and the difference is small ($P=0.49$) and all the complication were managed with case based approach. (Table 2)

The difference in the subjective satisfaction between two group is very small ($P=0.72$). In group A 17.4% (4/23) cases not satisfied because of financial burden and in group B 26.1% (6/23) cases because of tube related complications.

4. Discussion

Since the introduction of Silicone tube in management of PANDO it is being routinely used in all types of DCR surgery.¹⁵ One group of studies have strongly recommended the use of silicone tube in routine EXDCR for following advantages. It enhances the lacrimal pump action, ST delays the fibrous closure during the post operative healing period and helps in the patency of DCR, prevents granulation tissue formation in osteotomy and anastomosis, prevents common canalicular obstruction and corrects canalicular bent.^{6,7,13,16,17} While other groups of study strongly not favoured the use of silicone tube intubation in routine EXDCR for following disadvantages.

Table 1: Demographic details of patients, Eye involvement, presenting symptoms and duration of Symptoms.

Demography and Symptoms	Total (n=46)	Group A (n=23)	Group B (n =23)	P
Age (years)	48.3 +/- 16.4	52.2 +/-16.1	44.3 +/-15.9	P = 0.10
Female /Male	30/16	16/7	14/9	P = 0.75
Right eye/Left eye	27/19	15/8	12/11	P = 0.39
Epiphora Discharge/ Mucocele	34 12	13 10	21 02	P=0.01 P=0.01
Duration of Symptoms	9.6 months (4 – 16)	9.6 months (4 – 16)	9.2 months (5 – 16)	P= 1.0

Table 2: Postoperative complications and remedial actions taken in both APANDO and FPANDO.

Complications	Total (n= 46)	Group A (n =23)	Group B (n = 23)	Remedy
Cosmetic Blemish	5	1	4	Counseling
Punctal Slitting (erosion)	1	1	0	Loosening the Tube
Corneal erosion	2	0	2	Artificial drop
Conjunctival erosion	4	0	4	Artificial drop
Discomfort and FB sensation	5	1	4	Artificial drop
Stent road Extrusion (Looping)	5	1	4	Suturing tube knot to nasal cartilage
Tube loss	2	1	1	New tube intubation
Canalicular snaring	1	1	0	Loosening the tube
Granuloma Formation	3	2	1	Intralesional Triamcinolone 40mg/ml injection
Adhesion in nasal meatus	5	3	2	Intralesional Triamcinolone 40mg/ml injection
Difficulty in Tube removal	3	2	1	Use of 10% Xylocaine nasal spray.

Formation of granuloma around the tube, punctual erosion, corneal erosion, conjunctival erosion, stent road extrusion, stent loss, slitting or cheese wiring of puncta and canaliculi, ostium granuloma formation, secondary bacterial or fungal infection, nasal synechia formation, more consumption of surgical of time, intra operative canalicular trauma, pain while removing the tube and additional tube expense.^{3,5,6,8,9,16–18}

With diversity of outcomes from varies studies^{4,5,7,12,13} this study was done to know the efficacy and complications of Silicone tube with EXDCR in anatomical and functional PANDO.

The mean age of the patient is 48.3 +/-16.4 years, On gender involvement more Female patients 1.9:1, laterality of eye involvement and duration of symptoms are comparable to earlier studies.^{3,4,6,10,11,13}

Epiphora was the presenting symptoms in 74% (34/46) cases, discharge in 15% (7/46) case and mucocele in 11% (5/46) cases this is in concordance with earlier report.⁹ As per the Royal society of Ophthalmology, success of DCR considered when both anatomical and functional patency of the anastomoses. In our study 89.1% (41/46) cases had success at the end of 6 months and comparable to earlier report.^{4,6,12} Cumulative stent related complications observed during the follow up period is 24.0% (11/46). Stent road extrusion (looping of tube) in 10.9% (5/46) cases, granuloma around the tube in 6.5% (3/46) cases,

punctual slit in 2.2% (1/46) cases and tube loss in 4.4% (2/46) cases are comparable with a prospective study report from Nuhogu et al⁵ in their study of 53 cases of PANDO under went stent intubation and the stent related cumulative complications was 21% (11/53) cases.(P=0.80). More number of stent road extrusion in 10.8% (5/46) cases are observed in our study compare to earlier studies report of 1.8- 2.8%.^{3,6} The probable reason for more cases of stent road extrusion may be, we had equal number of clinically confirmed anatomical and functional PANDO cases (23/46). In a retrospective study by Monka et al³ 53 cases of failed primary DCR underwent silicone tube intubation and only one case had tube extrusion(P=0.09). In another retrospective study by Neena et al⁶ on 79 patients with PANDO 37 cases underwent tube intubation only one case developed stent road extrusion.(P=0.21) In the above two studies cases patients were not classified into anatomical or functional PANDO. In a report by Kim et al.¹³ 9 cases of anatomically patent but functionally failed DCR had stent and 33%(3/9) case had stent road extrusion and comparable. (P = 11). In our study 80% (4/5) cases with stent road extrusion are from functional PANDO group and comparable to reported rate of 33% (3/9) in functionally failed cases of DCR. Our observation of more number of tube extrusion in functional PANDO needs further study support.

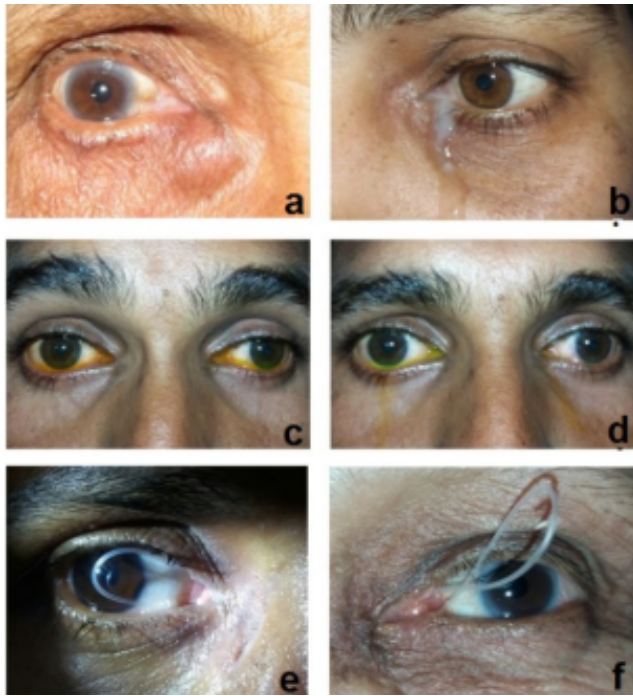


Fig. 1: Showing a. Right eye Mucocele, APANDO, b. Left eye positive regurgitation test, APANDO, c. Both eyes FDD test, d. Same patient in Figure c with Right eye positive FDD and FPANDO, e. Post EXDCR Stent road extrusion in Right eye APANDO, f. Post EXDCR Stent road extrusion in Left eye FPANDO

Regarding the patients satisfaction 21.7% (10 /46) responded negatively. Two main reasons were, additional financial burden for the tube and tube related complication. The same factors have been attributed for non of use silicone tube in EXDCR.³ Multiple sessions of counseling, eye health education and awareness on newer procedure would have reduced the number of subjectively unhappy patients.

On group comparison the mean age of patients, gender preference, laterality of the eye and duration of symptoms are not different between two groups. (Table 1)

Epiphora was the common presenting symptom in group B patients 91.3% (21/23) compare to group A patients 56.52(13/23) with a considerable difference between two group ($P=0.016$). In a retrospective study by Kim et al.¹³ all 13 patients with anatomically patent but functionally blocked primary EXDCR presented with epiphora and in an another study by Elomnem et al.¹² 20 cases of failed primary EXDCR presented with epiphora all are having anatomically patent but functionally failed DCR. In anatomical PANDO group more number of cases presented with discharge and mucocele 43.5% (10/23) cases compare to 8.7% (2/23) in functional PANDO and the difference is large ($P=0.016$). This observation is comparable to a prospective study of 100 patients with PANDO by Saiju

et al.⁴ All these 100 PANDO presented with discharge and positive syringing. Our observation on FPANDO Common presentation is epiphora and APANDO with discharge /mucocele. need to be supported by further studies

The assumptions on pathophysiology of nasolacrimal duct obstruction is both anatomical and functional; The initial process in lacrimal duct obstruction may be altered components of the tear or altered secretions in the nasal cavity around the duct opening. These factors induce ascending inflammation from nasal cavity and descending inflammation from the eye. This inflammation causes morphological and functional changes in the mucosal cells of the duct. This altered mucosal epithelial layer disturbs the normal structural and functional integrity of cavernous sinus plexuses around the lacrimal sac and duct. These cavernous plexuses are very essential in normal functioning of all parts of lacrimal pump. This reduced lacrimal pumping action delays tear drainage and alter the constituents of tear and nasal secretions which in turn increases tear secretion and presenting with epiphora. At this stage patient presents with epiphora and patent syringing. This vicious cycle continues and produces simultaneous shrinkage of cavernous body and closure of the duct lumen. These anatomical changes leading stagnation of mucin, tear waste products, dead and degenerated cells and inflammatory cells and the patient presents with discharge and positive syringing.² Eventhou stastically not significant ($P=0.10$) more number of younger (4-5th decade) patients in functional PANDO compare to anatomical PANDO may suggest that PANDO initially starts as FPANDO and later develops to APANDO. These observation also needs further larger sample studies.

The success rate was 78.3 % (18 /23 cases) in group A and 86.9% (20/23 cases) in group B and the difference is small ($P=0.69$). The success rate of 78.6% in group A appears less than the success reported by Saiju et al⁴. In Saiju et al.⁴ prospective study on 100 cases APANDO 44 patients underwent EXDCR with silicone stent intubation and 91% (40/44) cases epiphora was resolved but the difference is small($P=0.25$). The success rate of 86.95 % (20/23 cases) in group B patients is very much lower than earlier reports of 95% to 100%.^{12,13} Two prospective studies one by Kim et al¹³ 13 patients with anatomically patent but functionally failed EXDCR underwent stent intubation. All cases 100% (13/13) had resolution of epiphora ($P=0.001$) and another from Elmonem et al.¹² 20 cases with anatomically patent but functionally failed EXDCR underwent stent intubation, 90%(18/20)cases had resolution ($P=0.001$). Probable reasons for this large difference in the success rate are, in the above two studies^{12,13} all patients had primary EXDCR with anatomically patent but functionally failed duct. In a report from Neena et al⁷ their retrospective study group had 46 cases of functional PANDO underwent radiological and Dacrycystography tests to analyse the

causes for DCR failure. In 54% (25/46) patients there were sub clinical anatomical block at different levels of lacrimal drainage system. In the same study only 63% (29/46) were resolve following stent intubation. These subclinical blocks might have been cleared from previous EXDCR and the reason for 90 % - 100 % resolution rate in Elmonem et al and Kim et al studies.^{12,13}

Observed commulative complications rate during the follow up period like punctal erosion, conjunctival erosion, corneal erosion, FB sensation, granulation tissue formation, stent road extrusion, tube loss and cosmetic blemish due to stent looping (stent road extrusion) was high in group B patients 100% (23 /23 cases) compare to group A patients 56.5 % (13/23 cases)($P=0.001$). This higher rate of tube related complications are higher than reported rate from Nuhoglu et al.⁵($P= 0.006$). In a prospective study by Nuhoglu et al.⁵ among 223 patients with primary and secondary lacrimal duct obstruction 53 patients had non complicated PANDO. These 53 patients underwent EXDCR with tube intubation and the commulative complication rate was 23.0% (12/53); tube loss in 15% (8/53), punctual erosion in 2% (1/53), 2% (1/53) granulation tissue formation in 2% (1/53) and intranasal synechia formation in 2% (1/53) cases. Our study cannot explain the reasons for higher rate of tube related complication compare to Nuhoglu et al.⁵ study. The probable reason is in Nuhoglu et al.⁵ study cases were not grouped into APANDO and FPANDO and in this study 80% (4/5) of stent looping is in FPANDO group. The explanation for looping of the tube may be, presence of silicone tube in the sac and duct may augment the function of the whole lacrimal pump system. The spiraling actions of the lacrimal pump may propel the tube towards medial canthus and causing the tube looping. Other probability is when the distal ends of the tube are knotted there may be twist in the two limbs of the tube initiating the spiraling of tube and propelling. This aspect needs radiography assisted intraoperative and post operative studies. In this study more number of tube extrusion in 17% (4/23) cases is comparable to reports from Kim et al.¹³ ($P=0.37$).

There is no difference in the subjective satisfaction between two groups. In group A 82.6%(19/23) patients and in group B 73.9%(17/23) were happy ($P=0.72$). Common reason for dissatisfaction was looping of the stent causing congestion, FB sensation and cosmetic blemish in group B and financial burden in group A.

5. Conclusion

EXDCR with silicone tube intubation gives equal result in anatomical and functional PANDO. ($P=0.69$). Silicone stent related complications like tube extrusion, cosmetic blemish, corneal erosion, conjunctival erosion, punctual slitting and canalicular snaring are more in functional PANDO ($P=0.001$). Anatomically related complications like granuloma formation, adhesion in nasal cavity and

difficulty in stent removing are relatively more common in anatomical PANDO ($P=0.49$). More number of tube extrusion in functional PANDO needs further study. Lacunae in our study are small sample size, short follow up period. Grouping of functional PANDO not foolproof since we have not performed radiographic and DCG in functional PANDO. In educationally underprivileged population repeated counseling and eye health education has major role in subjective satisfaction.

6. Source of Funding

None.

7. Conflict of Interest

None.

References

1. Paulsen F. Pathophysiological Aspects of PANDO, Dacryolithiasis, Dry Eye, and Punctum Plugs. Berlin Heidelberg: Verlag; 2007. p. 15–27.
2. Komínek P, Rocca RCD, Rosenbaum S, Weber RK, Keerl R, Schaefer SD, et al. Diagnostics. Berlin Heidelberg: Verlag; 2007. p. 29–52.
3. Monka A, Zhungli S. Silicone Intubation in External Dacryocystorhinostomy. *Int J Sci Res (IJSR)*. 2015;12(4):1814–6.
4. Saiju R, Morse LJ, Weinberg D, Shrestha MK, Ruit S. Prospective randomised comparison of external dacryocystorhinostomy with and without silicone intubation. *Br J Ophthalmol*. 2009;93(9):1220–2.
5. Nuhoglu F, Sarıcı K, Ozdemir FE. Outcome of External Dacryocystorhinostomy with Bicanalicular Silicone Tube Stenting. *JAREM*. 2014;4:88–92.
6. Gul A, Duran M, Can E, Öztürk H, Aritürk N. The Effect of Silicone Tube Intubation in External Dacryocystorhinostomy. *Acta Med Anatol*. 2015;3(1):1–4.
7. Neena MP, Andrew RP. External dacryocystorhinostomy for the treatment of epiphora in patients with patent but non-functioning lacrimal systems. *Br J Ophthalmol*. 2010;94:233–5.
8. Rath S, Bothra N, Wani R, Ganguly A, Tripathy D. Primary nonendoscopic endonasal versus external dacryocystorhinostomy in nasolacrimal duct obstruction in children. *Indian J Ophthalmol*. 2017;65(10):1004–7.
9. Mukhtar SA, Jamil A, Z A. Efficacy of External Dacryocystorhinostomy (DCR) with and without Mitomycin-C in Chronic Dacryocystitis. *J Coll Physicians Surg Pak*. 2014;24(10):732–5.
10. Jo A, Lee SH, Song WC, Shin HJ. Effects of ostium granulomas and intralesional steroid injections on the surgical outcome in endoscopic dacryocystorhinostomy. *Graefe's Arch Clin Exp Ophthalmol*. 2018;256(10):1993–2000.
11. Pradeep B, Rajendran B. Double canalicular single tube intubation in DCR. *Indian J Ophthalmol*. 1983;31:329–30.
12. Elmonem A, Elhesy A. Effect of lacrimal silicone intubation in persistent epiphora after an anatomically successful but functionally failed dacryocystorhinostomy (Mansoura technique). *J Egypt Ophthalmol Soc*. 2013;106:74–7.
13. Kim NJ, Kim JH, Hwang SW, Chung HO, Lee J, Khwang YJ, et al. Lacrimal Silicone Intubation for Anatomically Successful but Functionally Failed External Dacryocystorhinostomy. *Korean J Ophthalmol*. 2007;21(2):70–3.
14. Lee BJ, Nelson CC, Lewis CD, Perry JD. External Dacryocystorhinostomy Outcomes in Sarcoidosis Patients. *Ophthalm Plast Reconstr Surg*. 2012;28(1):47–9.
15. Connell PP. Long term follow up of nasolacrimal intubation in adults. *Br J Ophthalmol*. 2006;90(4):435–6.

16. Singh M, Kamal S, Sowmya V. Lacrimal stents and intubation system: An insight. *Delhi J Ophthalmol.* 2015;26:14–9.
17. Min GK, Woo SS. Systematic review of benefit of silicone intubation in endoscopic DCR. *Clin Expe Otolaryngol.* 2018;11:81–8.
18. Muhammad Z, Tariq M, Jalis M, Khalid A. Is Silicone Intubation Necessary in Dacryocystorhinostomy? *Pak J Ophthalmol.* 2016;32(4):231–4.

Author biography

Vasu Narasimha Naik Eye Specialsit

Cite this article: Naik VN, Kumar V . **External Dacryocystorhinostomy with Silicone stent in Anatomical and Functional primary acquired nasolacrimal duct obstruction.** *IP Int J Ocul Oncol Oculoplasty* 2020;6(2):122-128.