

## An insight to the keratocystic tumour in the anterior mandible– A case report

Rakhi Chandak<sup>1</sup>, Runal Bansod<sup>2\*</sup>, Ramhari Sathawane<sup>3</sup>, Ashish Lanjekar<sup>4</sup>, Devendra Palve<sup>5</sup>, Pranali Thakare<sup>6</sup>

<sup>1,4</sup>Reader, <sup>2,6</sup>PG Student, <sup>3,5</sup>Professor and HOD, Dept. of Oral Medicine & Radiology, SDKS Dental College and Hospital, Nagpur, Maharashtra, India

**\*Corresponding Author: Runal Bansod**

Email: [runalbansod@gmail.com](mailto:runalbansod@gmail.com)

### Abstract

**Background:** Keratocystic odontogenic tumour has been identified as a "tumour" after its consistent neoplastic progression and detailed assessment of its biological behaviour and genetic abnormalities. Keratocystic odontogenic tumour can transform into more aggressive lesions such as ameloblastoma and primary intraosseous carcinoma very rarely.<sup>1</sup> This manuscript discusses an unusual case which presented as a diagnostic dilemma due to its occurrence in the anterior mandible due to its varied clinical and radiological features paralleling with the features of other similar pathologies occurring in the anterior mandible.

**Methods:** A 23 year old male patient presented to the outpatient department of Oral Medicine & Radiology with pain in his anterior mandibular teeth. After panoramic and cone beam computed tomographic scans, a unilocular radiolucency was seen suggestive of a tumour. Decortication of the lesion was done followed by application of Carnoy's solution through intraoral incision and the lesion was excised.

**Results:** The surgical procedures were performed without any complications. The patient was followed up for 6 months and no recurrence was noted post surgery.

**Conclusion:** Proper diagnosis, conservative treatment of the tumour, use of solutions like the Carnoy's solution & a long term follow up protocol plays a very marked role in the management of odontogenic keratocyst.

**Keywords:** keratocystic odontogenic tumour, Odontogenic keratocyst, Tumour, Mandible, Decortication, Carnoy's solution.

### Introduction

Odontogenic keratocyst has been renamed as keratocystic odontogenic tumour in 2005 by the World Health Organisation, thereby distinguishing the lesion from the orthokeratinizing variant, which is now considered an odontogenic keratocyst or orthokeratinized odontogenic cyst.<sup>1</sup> Odontogenic keratocyst is one of the most aggressive odontogenic cysts of the oral cavity and is known for its rapid growth and tendency to invade the adjacent tissues including the bone.<sup>2</sup> Odontogenic keratocyst (OKC) is a developmental, non-inflammatory chronic cyst that may be unilocular or multilocular.<sup>3</sup> 70% to 80% of keratocysts are most common in the mandible with a greater incidence at the angle extending upto the ascending ramus and forward into the body.<sup>2</sup> It is noted to be third most common odontogenic cyst after radicular and dentigerous cyst.<sup>8</sup>

Growth is chiefly in the anteroposterior dimension, and the lesions may attain remarkable size without significantly deforming the jaw skeleton.<sup>2</sup> Odontogenic keratocyst (OKC) is one of the most common developmental odontogenic cyst that arises from the dental lamina affecting the maxillofacial region. Keratocystic Odontogenic Tumour (KCOT) in the jaws arise from the cell rests of dental lamina and are usually seen during the second to fourth decades of life with a slight male predilection. The OKC is distinctive among jaw cysts given its tendency toward recurrence and aggressive clinical behavior.<sup>2</sup> It's the most common type of tooth derived cyst

due to presence of odontogenic epithelial remnants in different regions of jaw making it an aggressive cystic lesion.<sup>7</sup> Displacement of teeth adjacent to the cyst occurs more frequently than resorption.<sup>10</sup>

Maxillary OKC's are smaller in size as compared to the mandibular OKC's. They tend to cause bone expansion when they are large in size. No difference in site distribution was seen between unilocular and multilocular cysts.<sup>9</sup> These lesions can also present as a small and oval radiolucency between teeth, simulating a lateral periodontal cyst.<sup>10,11</sup> OKC's can have a simulating radiographic presentation as that of a residual apical periodontal cyst when they appear as a radiolucency. This benign condition can have a malignant transformation towards squamous cell carcinoma or ameloblastoma.<sup>7</sup> Histologically, the features of OKC include a thin epithelial lining & a corrugated tissue composed of thin irregular bundles of collagen consisting of fewer than six cell layers & also contains islands of epithelium that may represent daughter cysts. The epithelium of many cysts have a tendency to separate from the underlying cystic wall. OKCs show a friable thin wall which is often difficult to enucleate from the bone in one piece and have satellite cysts in their fibrous wall. Hence OKCs have a tendency to recur.<sup>11</sup>

We present a rare case of odontogenic keratocyst, in the anterior mandible in a 23 old year male patient having typical radiographic features characteristic of a keratocyst.

### Case Report

A 23 year old male patient reported to the department of Oral Medicine & Radiology at Swargiya Dadasaheb Kalmegh Smruti Dental College & Hospital, Nagpur with the chief complaint of pain in the lower anterior front tooth region of jaw since 1 month. Patient's general condition was normal. On extraoral examination, no inspectory findings were evident, while on palpation the left lower border of mandible was tender. On intraoral examination, the inspectory findings revealed suture with 31, 32, 34 (Fig. 1) along with mild gingival inflammation in the same region. There was physiologic mobility of 34 due to missing 33 along with mesial tilting. No obliteration of the buccal vestibule was noted. Palpatory findings revealed tenderness on percussion with 31, 32, 34 and tenderness in the region of buccal vestibule with respect to 33.

Panoramic radiograph revealed a unilocular radiolucency in the mandibular anterior region extending from mesial root of 36 to mesial root of 46. Margins appeared well defined, scalloped and corticated. Internal structure appeared to be completely radiolucent. Surrounding structures showed mesially inclined 34, laterally inclined 32 and impacted 33 (Fig. 2).

CBCT (Cone Beam Computed Tomography) examination revealed a unilocular radiolucency in the mandibular anterior region extending from mesial root of 36 to mesial root of 46 with margins well defined and corticated. Internal structure appeared completely radiolucent and surrounding structures showed mesially inclined 34, 35, laterally inclined 32 and impacted 33.

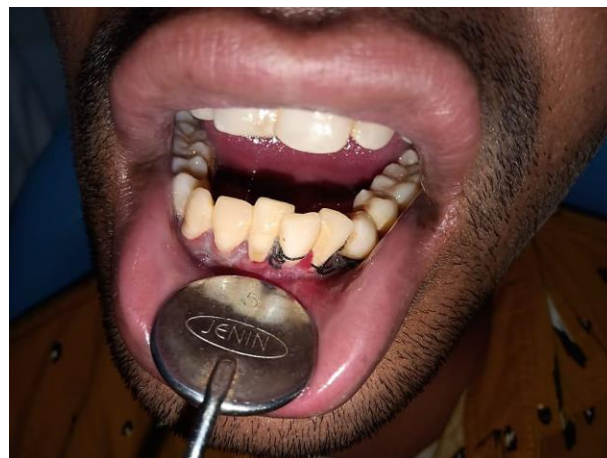Size of the lesion appeared to be approx.7 cms. Shape appeared to be oval (Fig. 3).

Under general anaesthesia the lesion was exposed through intraoral incision. It contained white, cheesy material. The lesion was curetted out completely with decortication of the lesion followed by application of carnoy's solution. The curetted tissue was then sent for histopathologic examination (Fig. 6).

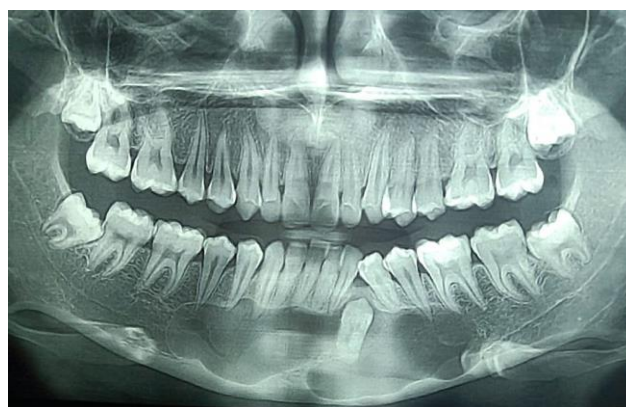On histopathologic examination, the H & E stained sections showed epithelium and connective tissue arranged in cystic configuration. The epithelium was 6-10 layers thick, parakeratinized, stratified squamous type with surface corrugations. The basal cell layer showed characteristic tomb stone appearance with palisaded nuclei. The epithelium had flat interface with the underlying connective tissue. The stroma consisted of collagen fibre bundles arranged irregularly with few blood capillaries. Hence, a final diagnosis of odontogenic keratocyst was made<sup>4</sup> (Fig. 7).

The patient was followed up regularly. A post-operative radiographic examination was done by taking an OPG which

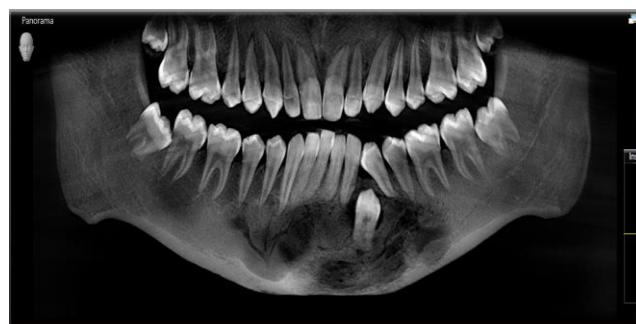revealed healing of bone in the anterior mandibular region (Fig. 8).



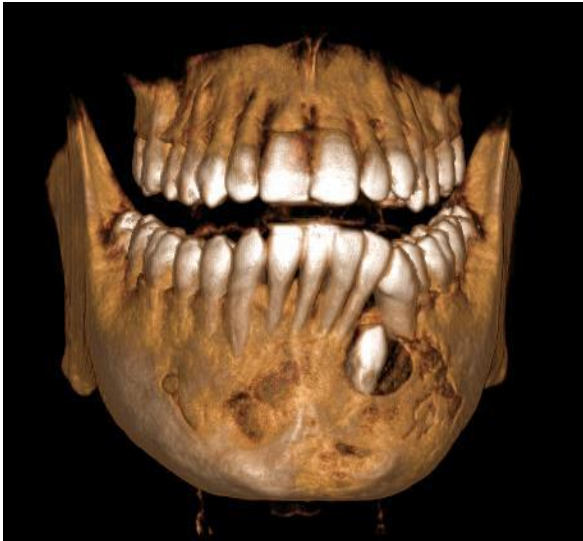
**Fig. 1:** Photograph showing sutures with lower anterior teeth region



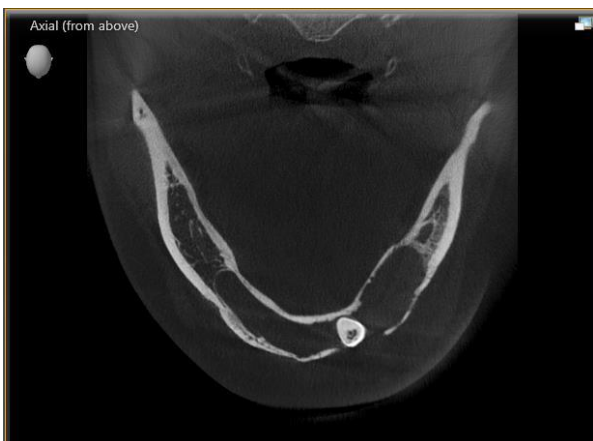**Fig. 2:** Orthopantomogram showing a unilocular radiolucency in the mandibular anterior region extending from 36 to 46



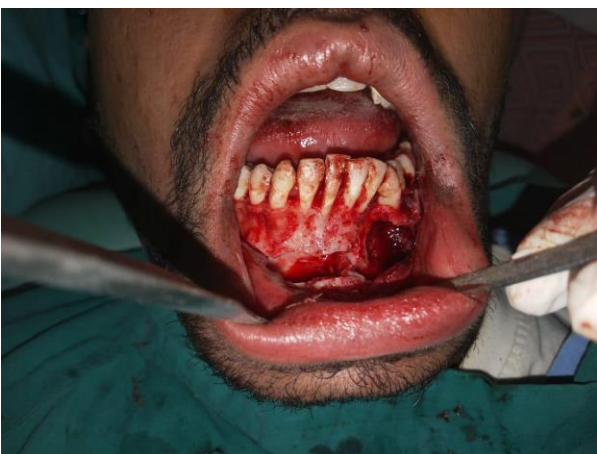**Fig. 3:** CBCT imaging showing panoramic view. Unilocular radiolucency seen extending from 36 to 46 along with impacted 33



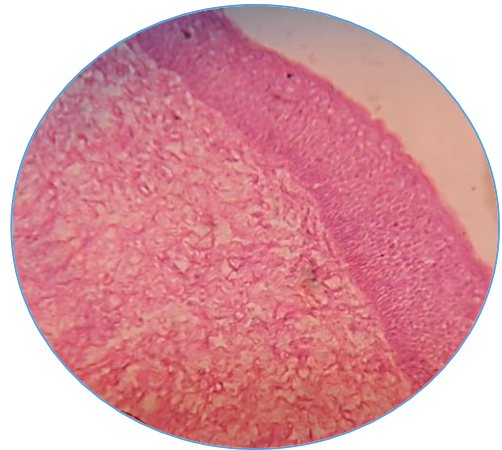
**Fig. 4:** 3D reconstruction CBCT view showing impacted 33



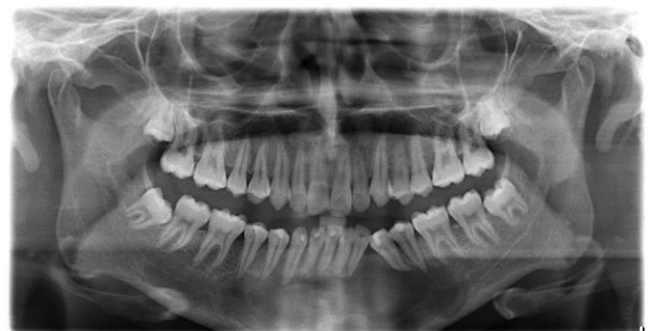**Fig. 5:** Axial view on CBCT showing thinning of cortical plates and resorption of buccal cortical plate in 33 region



**Fig. 6:** Photograph showing decortication of the lesion using Carnoy's solution



**Fig. 7:** High power view (40x)- showing H & E stained section having epithelium which is parakeratinsed stratified squamous type, corrugated surface epithelium, the epithelium is 6-10 cell layer thick. The basal cell layer is showing characteristic tomb stone appearance with palisaded nuclei



**Fig. 8:** Post operative photograph showing healing of bone in the anterior region of mandible

### Discussion

Odontogenic keratocysts (OKCs) are considered benign cysts of odontogenic origin that account for about 10% of all odontogenic cysts. Philipsen<sup>14</sup> in 1956 first used the term odontogenic keratocyst.<sup>4</sup> The most striking feature of OKC is its capacity for recurrence. There have been many explanations regarding the high occurrence rate of an OKC. There is incrimination of the proliferative OKC for both i.e., having a recurrence and a locally aggressive behaviour (Browne, 1970<sup>15</sup>; Toller 1971<sup>16</sup>).<sup>13</sup> The cyst has a thin wall that can be easily perforated (Browne & Miller 1969)<sup>17</sup> & incompletely removed. Also, the cysts extent during surgery may be difficult to determine. This is mainly due to the presence of small cysts within the walls “budding” and also the epithelium may proliferate downwards. Main (1970)<sup>18</sup> studied the growth rate of OKC & stated that it may not be greater as compared to the other jaw cysts. Later he summed up with Toller in 1971 and they both stated that their growth is more unremitting and showed a higher mitotic value in

OKC epithelial linings as compared to non-odontogenic cysts & radicular cysts. Browne & Gough, 1972;<sup>19</sup> Toller 1967<sup>20</sup> reported malignant transformation of OKC.

Gorlin & Goltz,<sup>21</sup> 1980 stated the occurrence of OKC in association with basal cell naevus syndrome, a condition characterised by multiple basal cell carcinomas, OKC & skeletal anomalies.<sup>13</sup> OKCs arise from the dental lamina and are characterised by a cystic space containing desquamated keratin and a lumen lined by epithelium that is generally 8-10 cell layers thick and surfaced by parakeratin.<sup>4-6</sup> One of the most important feature of this cyst is budding of the cyst lining into connective tissue.

OKCs are characterised by an aggressive behaviour with a relatively high recurrence rate, particularly when OKCs are associated with syndromes.<sup>4,5,7</sup> Multiple OKCs are typically associated with the nevoid basal cell carcinoma syndrome (NBCCS), an autosomal dominant disease.<sup>4</sup> OKCs are commonly located in the mandibular third molar regions, but may occur anywhere in the jaws, including the mandibular bone. Radiographically, OKCs appear as a round or ovoid radiolucency, which may be multilocular or unilocular.

Diagnosis of the unilocular cyst is based on histology.<sup>6</sup> Radiological imaging, mainly computed tomography (CT) and, in selected cases, magnetic resonance imaging (MRI), plays an important role in the diagnosis and management of OKCs. The knowledge about various radiological features of OKCs is essential for the correct diagnosis and treatment planning. Clinical and radiological findings in combination can help in evaluating the extent of the lesions and its relationships with the adjacent structures.<sup>4</sup>

There are some odontogenic cysts that need to be differentiated from OKC. The most common odontogenic cyst, associated with an unerupted tooth is a dentigerous cyst. It lacks the basal palisading and corrugated parakeratinised surface. OKC and orthokeratinised odontogenic cyst share some close association, the only difference being that its orthokeratinised and not parakeratinized. It too lacks the palisaded basal layer. A calcified odontogenic cyst can be differentiated from an OKC as it has distinctive ghost cells and a basal palisading. An ameloblastoma shows a feature which recapitulates the developing tooth. It shows a loosely arranged stellate reticulum radiographically.<sup>22</sup> The differentiation between all these cysts is quite difficult both clinically and radiographically. OKCs cause less bone expansion than dentigerous cysts. OKCs present a scalloped periphery, while dentigerous cysts have a smooth periphery.<sup>22</sup>

Due to high recurrence rate of OKC, its very mandatory to perform periodic clinical as well as radiographic evaluation and monitoring of patients with surgically treated OKCs, hence keeping a check on its recurrence.<sup>4</sup>

Multiples recurrent lesions and primary OKCs with aggressive clinical behaviour, including perforation of the cortical plates of the jaws or extension into the adjacent tissues, extensive lesions, and presence in the mandibular molar-ramus region were the main factors in the decision-making process for radical resection. When possible, it was acceptable to start with a conservative approach, including marsupialization followed by enucleation, in particular in young patients or elderly patients who are medically compromised. Long term follow-up remains important to monitor possible disease recurrence.

### Conclusion

KCOT holds an aggressive treatment strategy due to its aggressive nature. Clinicians should focus on proper diagnosis, conservative treatment, use of solutions like Carnoy's solution, cryosurgery & long term follow up protocol in management of OKC.

This case report enlightens us about the occurrence and management of OKC in uncommon sites, i.e. the anterior mandible. Also clinical, radiological & histological findings should be correlated, as this will prevent recurrence rate.

Hence early diagnosis, treatment & proper follow up of the patients plays an important role in cases of OKC's.

### Source of Funding

None.

### Conflict of Interest

None.

### References

1. Nair KK, Lingappa A, Rangaiah P, Vittobarao PG. Keratocystic odontogenic tumor: A case report and review of literature. *J Indian Acad Oral Med Radiol.* 2015;27(2):253-8.
2. Gnanaselvi UP, Kamatchi D, Sekar K, Narayanan BS. Odontogenic keratocyst in anterior Mandible: An interesting case report. *J Indian Acad Dent Spec Res.* 2016;3(1):22-4.
3. Ramadevi S, M. Kumar NM, K. Khartik. Odontogenic Keratocyst – A case report. *Indian J Mednodent Allied Sci.* 2015;3(2):127-30.
4. Borghesi A, Nardi C, Giannitto C, Tironi A, Maroldi R, Di Bartolomeo F, Preda L. Odontogenic keratocyst: imaging features of a benign lesion with an aggressive behaviour. *Insights into imaging.* 2018;9(5):883-97.
5. Madras J, Lapointe H. Keratocystic odontogenic tumour: reclassification of the odontogenic keratocyst from cyst to tumour. *J Can Dent Assoc.* 2008;74(2):165.
6. O'Neill R, Al-Hezaimi K. Identification of an odontogenic keratocyst and treatment with guided tissue regeneration: case report. *J Can Dent Assoc.* 2011;77:b6.



7. Sheethal HS, Rao K, Umadevi HS, Chauhan K. Odontogenic keratocyst arising in the maxillary sinus: A rare case report. *J Oral Maxillofac Pathol.* 2019;23(Suppl 1):74-80
8. Bohra A, Udawat V, Bhemappa A, Arya S. Keratocystic odontogenic tumor of mandible. *Med J Dr. DY Patil Univ.* 2016;9(3):403-7.
9. Webb JD, Brockbank J. Treatment of the odontogenic keratocyst by combined enucleation and cryosurgery. *Int J Oral Surg.* 1984;13:506-10.
10. Tae GI, Hoe-Kyung H. Diagnostic ability of differential diagnosis in ameloblastoma and odontogenic keratocyst by imaging modalities and observers. *Korean J Oral Maxillofac Radiol.* 2006;36:177-82.
11. Singh M, Gupta KC. Surgical treatment of odontogenic keratocyst by enucleation. *Contemp Clin Dent.* 2010;1(4):263-7.
12. Anwar BB, Mansour AA. Treatment of mandibular odontogenic keratocysts. *Oral Surg Oral Med Oral Pathol Oral Radiol Endod.* 1998;86:42-7.
13. Lund VJ. Odontogenic keratocyst of the maxilla: a case report. *Br J Oral Maxillofac Surg.* 1985;23(3):210-5.
14. HP P. Om keratocyster (kolesteatomer) i kaeberne. *Tandlaegebladet.* 1956;60:963-71.
15. Browne RM. The odontogenic keratocyst: Clinical aspects. *Br Dent J.* 1970;128:225.
16. Toller PA. Autoradiography of explants from odontogenic cysts. *Br Dent J.* 1971;131:57-61.
17. Browne RM, Miller WA. Rupture strength of capsules of odontogenic cysts in man. *Arch Oral Biol.* 1969;14:1351-4.
18. Main DM. The enlargement epithelial jaw cysts. *Odontol Revy.* 1970;21:29-49.
19. Browne RM, Gough NG. Malignant change in the epithelium lining odontogenic cysts. *Cancer.* 1972;29:1199-1207.
20. Toller PA. Origin and growth of cysts of the jaw. *Ann R Coll Surg Engl.* 1967;40:306-36.
21. Gorlin RJ, Goltz RW. Multiple nevoid basal cell epithelium, jaw cysts and bifid rib: a syndrome. *N Engl J Med.* 1960;262:908-12.
22. Bang KO, Shenoi RS, Dahake RN, Budhraj NJ. A rare case report of orthokeratinized odontogenic keratocyst associated erupting complex odontome with impacted mandibular molar. *Indian J Multidiscip Dent.* 2016;6(2):119-23.

**How to cite this article:** Chandak R, Bansod R, Sathawane R, Lanjekar A, Palve D, Thakare P. An insight to the keratocystic tumour in the anterior mandible– A case report. *IP Int J Maxillofac Imaging.* 2020;6(1):15-9.